

## Accuracy of the smartphone-based nonmydriatic retinal camera in the detection of sight-threatening diabetic retinopathy

Vijayaraghavan Prathiba, Ramachandran Rajalakshmi, Subramaniam Arulmalar, Manoharan Usha, Radhakrishnan Subhashini, Clare E Gilbert<sup>1</sup>, Ranjit Mohan Anjana, Viswanathan Mohan

**Purpose:** To evaluate the sensitivity and specificity of smartphone-based nonmydriatic (NM) retinal camera in the detection of diabetic retinopathy (DR) and sight-threatening DR (STDR) in a tertiary eye care facility. **Methods:** Patients with diabetes underwent retinal photography with a smartphone-based NM fundus camera before mydriasis and standard 7-field fundus photography with a desktop mydriatic fundus camera after mydriasis. DR was graded using the international clinical classification of diabetic retinopathy system by two retinal expert ophthalmologists masked to each other and to the patient's identity. The sensitivity, specificity, positive predictive value (PPV), and negative predictive value (NPV) to detect DR and STDR by NM retinal imaging were assessed. **Results:** 245 people had gradable images in one or both eyes. DR and STDR were detected in 45.3% and 24.5%, respectively using NM camera, and in 57.6% and 28.6%, respectively using mydriatic camera. The sensitivity and specificity to detect any DR by NM camera was 75.2% (95% confidence interval (CI) 68.1–82.3) and 95.2% (95%CI 91.1–99.3). For STDR the values were 82.9% (95% CI 74.0–91.7) and 98.9% (95% CI 97.3–100), respectively. The PPV to detect any DR was 95.5% (95% CI 89.8–98.5) and NPV was 73.9% (95% CI 66.4–81.3); PPV for STDR detection was 96.7% (95% CI 92.1–100) and NPV was 93.5% (95% CI 90.0–97.1). **Conclusion:** Smartphone-based NM retinal camera had fairly high sensitivity and specificity for detection of DR and STDR in this clinic-based study. Further studies are warranted in other settings.

**Key words:** Nonmydriatic fundus photography, sight-threatening diabetic retinopathy, smartphone retinal imaging

Diabetic retinopathy (DR) is an important microvascular complication of diabetes mellitus (DM). In 2017, there were 451 million (age 18–99 years) people with DM worldwide and by 2045 this is expected to increase to 693 million.<sup>[1]</sup> The global prevalence of DR and sight-threatening DR (STDR) among individuals with DM was reported to be approximately 35% and 10%, respectively.<sup>[2]</sup> DR is now one of the leading causes of preventable blindness. Improvement in screening modalities and treatment options would help reduce the health burden due to DR and improve the quality of life. DR screening has been shown to be a cost-effective method of preventing diabetes-related vision loss.<sup>[3]</sup> Advances in retinal imaging could potentially transform the management of people with diabetes, and help reduce health care costs and resources.<sup>[3]</sup>

Early diagnosis of DR is possible by well-planned national level screening programs, which are integrated with diabetes management. Fundus photography for DR screening is globally accepted and adopted a screening tool for DR.<sup>[4]</sup> Traditional fundus cameras offer good-quality images but are bulky, office-based, technician-dependent, often need mydriasis, and are expensive.<sup>[5]</sup> Less expensive and nonmydriatic (NM) retinal

cameras are now available and some are also manufactured in India. An earlier study showed lower sensitivity and specificity of conventional NM retinal imaging to detect DR in India.<sup>[6]</sup> In that study, the sensitivity and specificity to detect any DR was 58.8% and 69.1%, respectively by grader 1 and grader 2 it was 57.3% and 68.3%, respectively.<sup>[6]</sup> Most smartphone-based imaging devices for DR detection require mydriasis.<sup>[7]</sup> NM smartphone-based retinal cameras manufactured in India have not been adequately evaluated.<sup>[8,9]</sup> The current study assessed the accuracy of smartphone-based NM retinal imaging cameras manufactured in India in the detection of DR and STDR compared with conventional desktop mydriatic fundus camera.

### Methods

#### Study population and design

In this single visit, prospective cross-sectional validation clinic-based study, patients attending the ophthalmic department of a tertiary care diabetic center were recruited. The duration of the study was 6 months, from June to November

This is an open access journal, and articles are distributed under the terms of the Creative Commons Attribution-NonCommercial-ShareAlike 4.0 License, which allows others to remix, tweak, and build upon the work non-commercially, as long as appropriate credit is given and the new creations are licensed under the identical terms.

For reprints contact: [reprints@medknow.com](mailto:reprints@medknow.com)

Cite this article as: Prathiba V, Rajalakshmi R, Arulmalar S, Usha M, Subhashini R, Gilbert CE, et al. Accuracy of the smartphone-based nonmydriatic retinal camera in the detection of sight-threatening diabetic retinopathy. Indian J Ophthalmol 2020;68:S42-6.

#### Access this article online

##### Website:

[www.ijo.in](http://www.ijo.in)

##### DOI:

10.4103/ijo.IJO\_1937\_19

#### Quick Response Code:



Madras Diabetes Research Foundation and Dr. Mohan's Diabetes Specialties Centre, Chennai, Tamil Nadu, India, <sup>1</sup>London School of Hygiene and Tropical Medicine, London, UK

**Correspondence to:** Dr. Vijayaraghavan Prathiba, Dr. Mohan's Diabetes Specialties Centre and Madras Diabetes Research Foundation, 6, Conran Smith Road, Gopalapuram, Chennai - 600 086, Tamil Nadu, India. E-mail: [drprathiba@drmoans.com](mailto:drprathiba@drmoans.com)

Received: 23-Oct-2019

Revision: 26-Nov-2019

Accepted: 28-Nov-2019

Published: 17-Jan-2020

2018. Adults aged 18–65 years with documented type 2 DM and who were willing to undergo retinal photography with two fundus cameras were included in the study. Diabetic patients who had a history of allergy to topical tropicamide, who had media opacities, like dense cataract or total vitreous hemorrhage, and if they had any contraindication/unwilling for mydriasis were excluded.

### Baseline examination

A complete medical and ophthalmic history was elicited regarding duration and type of diabetes, any visual symptoms, history of laser photocoagulation or cataract surgery, allergy to topical medications, and family history of glaucoma. Demographic details such as name, age, and gender were entered from the electronic medical record. Visual acuity testing was recorded for both distance and near vision by Snellen's chart placed at 6 m and 33 cm, respectively. Intraocular pressure was measured by noncontact tonometer (CT-80; Topcon, Tokyo, Japan).

### Retinal imaging

Four field retinal images of both eyes were taken using the fundus on phone (FOP) smartphone-based nonmydriatic retinal imaging camera (FOP NM- 10; Remedio Innovative Solutions Pvt. Ltd Bangalore, India) [Fig. 1]. The four fields were, namely, macula, nasal to disc, superior temporal, and inferior temporal quadrants. After adequate mydriasis using topical 1% tropicamide, seven-field retinal imaging with a desktop mydriatic fundus camera (Zeiss FF450, Jena, Germany) was performed. The retinal images from both the cameras were then graded independently by two medical retina specialists using the international clinical classification of diabetic retinopathy grading system (ICDR).<sup>[10]</sup> It was not possible to mask the graders to camera type, but sets of images were randomized before grading. Images from both cameras were graded using the same laptop. STDR was classified as severe nonproliferative DR (NPDR), proliferative DR (PDR), and diabetic macular edema (DME) in one or both eyes. DME was defined as the presence of definite hard exudates within one disc diameter of the center of the macula.<sup>[11]</sup> For bilateral retinopathy, the grade of DR of the worse eye was considered as the final DR grade for the patient. The ophthalmologists were masked to the diagnosis of DR and to each other's findings. The third ophthalmologist adjudicated in case of a disagreement between the two ophthalmologists.

### Outcome variables

- a) The quality of retinal photographs of both retinal imaging systems was assessed. Image quality was graded on 0 to 4 scale:<sup>[9,12]</sup> Grade 0-ungradable (no retinal details visible due



**Figure 1:** (a and b) Remedio fundus on phone nonmydriatic camera

to media opacities such as dense cataract or total vitreous hemorrhage); Grade 1-poor (only gross retinal changes detectable such as hemorrhages and dense hard exudates); Grade 2-satisfactory (major retinopathy details visible; minor degrees of retinopathy and subtle new vessels not clearly detectable); Grade 3-good (most of retinopathy changes clear and detectable); Grade 4-excellent (lesions clearly visible)

- b) The sensitivity and specificity for the detection of any DR and STDR were determined for smartphone NM cameras against the gold standard conventional mydriatic camera. The positive and negative predictive values were estimated.

### Quality assurance

The quality of photographs taken was periodically assessed and monitored by the senior optometrists and the principal investigator. The graders were masked to diagnosis of DR and patient identity. A system of fundus photographs management and retrieval was established. Standard reporting and data entry format was maintained.

### Ethical requirements

Approval of the study protocol was obtained from the Institutional Ethics Committee of the Madras Diabetes Research Foundation and written informed consent was provided by all the patients who participated in the study. The identity of participants and data generated in the study was handled in strict confidentiality. Data were available only to physicians involved in the study and to the regulatory authorities.

### Statistical analysis

Data were analyzed using statistical analysis software (SAS, version 9.2, SAS Institute, and Cary NC). The sensitivity and specificity for detecting any DR and STDR of varying degrees of severity were calculated using the  $2 \times 2$  tables for the smartphone-based nonmydriatic camera where the gold standard was dilated fundus photography using the desktop mydriatic fundus camera. The 95% CIs for sensitivity, specificity, positive and negative predictive values were calculated. Agreement between smartphone-based nonmydriatic fundus photography and 7-field mydriatic fundus photography was assessed using the kappa statistic.

## Results

Images from 245 people with diabetes were used in the analysis. The mean age of people with diabetes was  $53.2 \pm 8.9$  years and 65% were males. The mean duration of diabetes was  $12.34 \pm 6.5$  years.

### Photographic quality assessment

58% of photographs taken by FOP NM camera were graded as excellent or good and 33% were satisfactory [Table 1]. Only 9% of photographs were graded poor. One eye of one patient (1/490 eyes) was ungradable due to cataract by FOP NM camera but had gradable images in the other eye. By Zeiss camera, 86.6% of photographs taken were either excellent or good. All photographs taken with a Zeiss camera were gradable. The difference in quality of images was not statistically significant between the two cameras (Likelihood ratio = 15.998,  $P = 0.382$ ).

### DR grading by two cameras

DR was detected in 45.3% ( $n = 111$ ) by the FOP NM camera and in 57.6% ( $n = 141$ ) by the standard mydriatic camera. Mild NPDR was detected in 9.4% using the FOP NM camera compared with

15.9% by the standard mydriatic camera. This difference was not observed in the higher grades of DR. DME and STDR were detected in 22% ( $n = 54$ ) and 24.5% ( $n = 60$ ) eyes, respectively by the NM camera and 26% ( $n = 64$ ) and 28.6% ( $n = 70$ ) by standard mydriatic camera, respectively [Figs. 2 and 3]. About 5 patients (2%) who were diagnosed with no DR using the mydriatic camera showed NPDR in the FOP NM camera. The different grades of DR detected by NM camera and the standard mydriatic camera are shown in Table 2.

**Sensitivity and specificity**

The sensitivity and specificity to detect any DR by FOP NM camera was 75.2% (95% CI 68.1–82.3) and 95.2% (95% CI 91.1–99.3), compared with the Zeiss camera [Table 3]. The degree of agreement using  $\kappa$  statistic between FOP NM and Zeiss camera for any DR and NPDR was 0.67 (95% CI 0.59, 0.77  $P < 0.001$ ) and 0.66 (95% CI 0.57, 0.75  $P < 0.001$ ), respectively. The sensitivity and specificity to detect STDR by FOP NM camera was 82.9% (95% CI 74.0–91.7) and 98.9% (95% CI 97.3–100), compared to the Zeiss camera. The degree of agreement using  $\kappa$  statistic, between FOP NM and Zeiss camera for PDR, DME, and STDR were 0.92 (95% CI 0.82, 1  $P < 0.001$ ), 0.86 (95% CI 0.79, 0.93  $P < 0.001$ ), 0.85 (95% CI 0.77, 0.92  $P < 0.001$ ), respectively.

**Discussion**

The sensitivity and specificity in the detection of referral-warranted DR are of fundamental importance for screening programs.<sup>[13]</sup> The British Diabetic Association considers 80% sensitivity and 95% specificity for a viable DR screening program.<sup>[14]</sup> In this study, we report that the FOP NM camera showed fairly good sensitivity and specificity for the detection of STDR. It also had fairly high sensitivity, specificity, positive and negative predictive value for detection of DME. In an earlier study while using the mydriatic smartphone camera for STDR, the sensitivity was 87.9% and specificity 94.9% compared to conventional photography.<sup>[9]</sup> The sensitivity ranged from 64% to 97.9% and specificity ranged from 65.6% to 98% for detection of DR in a systematic review that evaluated the validity of nonmydriatic retinal photos, compared to seven-standard stereoscopic 30° field photographs.<sup>[15]</sup>

Currently, both desktop and handheld nonmydriatic cameras are available. The desktop nonmydriatic cameras include Trinethra (Forus, Bangalore), Topcon TRC-NW8FPLUS (Topcon, Tokyo, Japan), Icam (Optovue, U.S.A), Visucam 200 (Carl Zeiss, Jena, Germany), and Canon CR-2 (Canon Medical Systems, Netherlands). These cameras are relatively more expensive and heavy in weight; they are restricted to office-based procedures.<sup>[5]</sup> While the image

quality in some of the cameras in the Indian dark iris eyes is questionable,<sup>[6]</sup> these cameras reportedly perform better in Caucasian light iris eyes.<sup>[16]</sup>

The handheld nonmydriatic cameras include PanOptic ophthalmoscope (WelchAllyn, New York, USA), Pictor (Volk Optical Inc, Mentor, OH.), Smartscope PRO (Optomed Oy, Oulu, Finland) and Versacam (Nidek, Japan). Pictor (Volk Optical) handheld nonmydriatic camera has been evaluated for the detection of STDR; the sensitivity and specificity were 64%–88% and 72%–84%, respectively.<sup>[17]</sup> A recent study in India has compared a portable nonmydriatic handheld Smartscope fundus camera with dilated desktop Topcon images for detection of DR based on the grading by two retina specialists. A sensitivity of 88% and 82% were reported by the two graders, respectively and high specificity of 99% by both graders for detection of STDR.<sup>[18]</sup> The CAMRA study<sup>[19]</sup> compared DR detection from retinal images obtained by three cameras; mydriatic handheld i-phone imaging system with a 20D lens (video mode and screenshots), nonmydriatic desktop camera, and mydriatic desktop camera. The sensitivity of the

**Table 1: Quality of retinal photographs with the two modes of fundus photography**

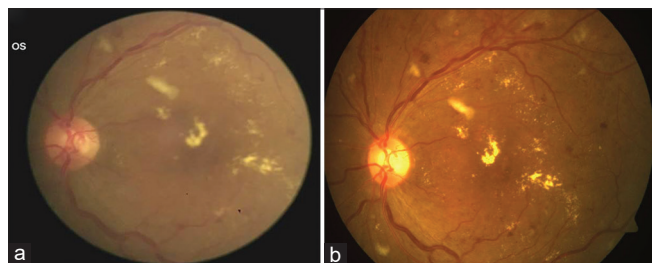
Image quality	FOP nonmydriatic camera		Zeiss mydriatic camera	
	n	%	n	%
Excellent	32	13.1%	46	18.8%
Good	110	44.9%	166	67.8%
Satisfactory	81	33%	30	12.2%
Poor	22	9%	3	1.2%

FOP: Fundus on Phone

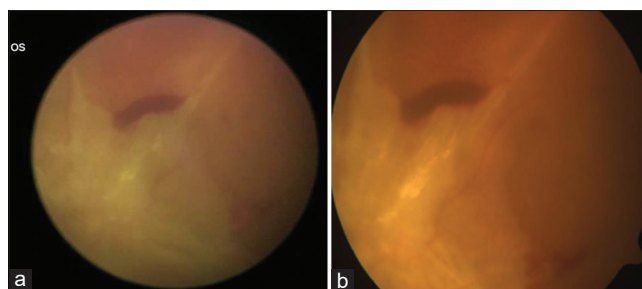
**Table 2: The DR severity by fundus on phone (FOP) nonmydriatic camera and Zeiss mydriatic camera**

FOP NM camera	ZEISS mydriatic camera			Total n (%)
	No DR n (%)	NPDR n (%)	PDR n (%)	
No DR n (%)	99 (40.4)	35 (14.3)	0	134 (54.7)
NPDR n (%)	5 (2)	91 (37.1)	1 (0.4)	97 (39.5)
PDR n (%)	0	1 (0.4%)	13 (5.3%)	14 (5.8)
Total n (%)	104 (42.4)	127 (51.8)	14 (5.7)	245 (100)

Linear trend value=138.8,  $P < 0.001$ , DR: Diabetic Retinopathy; NPDR: Nonproliferative DR; PDR: Proliferative DR



**Figure 2: Retinal image showing sight-threatening diabetic retinopathy (severe diabetic macular edema). (a) by Remidio fundus on phone nonmydriatic camera. (b) by Zeiss mydriatic fundus camera**



**Figure 3: Advanced diabetic eye disease (proliferative diabetic retinopathy with fibrovascular proliferation) (a) by Remidio fundus on phone nonmydriatic camera (b) by Zeiss mydriatic fundus camera**

**Table 3: Sensitivity, specificity, and positive predictive and negative predictive values of any DR and different grades of DR by Fundus on Phone nonmydriatic camera in comparison to Zeiss mydriatic camera**

	Sensitivity % (95%CI)	Specificity % (95% CI)	PPV% (95% CI)	NPV% (95% CI)
GRADE				
Any DR	75.2% (68.1,82.3)	95.2% (91.1,99.3)	95.5% (99.8,98.5)	73.9% (66.4,81.3)
NPDR	71.6% (63.8,79.5)	94.9% (90.9,98.9)	93.8% (89.0,98.6)	75.7% (68.8,82.6)
PDR	92.9% (79.4,100)	99.6% (98.7,100)	92.9% (66.1,99.8)	99.6% (97.6,99.9)
DME	82.8% (73.6,92.1)	99.4% (96.9,99.9)	98.2% (90.1,99.9)	94.2% (90.9,97.5)
STDR	82.9% (74.0,91.7)	98.9% (97.3,100)	96.7% (92.1,100)	93.5% (90.0,97.1)

DR: Diabetic Retinopathy; NPDR: Nonproliferative DR; PDR: Proliferative DR; DME: Diabetic Macular Edema; STDR: Sight threatening DR; PPV: Positive predictive value; NPV: Negative predictive value

handheld i-phone imaging system was 59% for the detection of STDR. The main limitation of handheld cameras is consistently maintaining the crucial manual alignment of the illuminating beam with optical axis for good quality images.<sup>[5]</sup> Quality of the retinal images is very critical for successful implementation of DR screening programs. In this study using FOP NM camera, the image quality of over 91% of the retinal photographs was graded satisfactory or better and hence the STDR detection was high.

The FOP NM camera has many advantages as it is light, compact, and portable and this study gave fairly high sensitivity and specificity to detect STDR. Pharmacological dilatation of pupils is not necessary, making it ideal for both the care receiver and provider. Thus, there is no risk of any allergy due to mydriatic eye drops or the risk of angle-closure glaucoma. There is no photosensitivity and temporary reduction of vision so that the patients could continue with their daily work after retinal photography. The time taken for the procedure is substantially reduced and this improves patient compliance, which is important as they need lifelong DR assessment.

The limitations of the FOP NM camera are that acquisition of images is difficult in patients with small pupils and when media is hazy due to advanced cataracts, however, images can also be taken after mydriasis by this camera. Though the FOP NM camera can be handheld, it preferably needs a portable table and chin rest for easy patient stabilization during the acquisition of images, as was used in this study. We have also excluded the patients with ungradable images in both eyes with FOP NM camera from the analysis. Our study was undertaken in an ophthalmic clinic, and further studies are needed in settings where DR screening may take place i.e. in physicians' clinic or noncommunicable diseases clinics where the proportion of patients with significant lens opacities or corneal opacity is likely to be higher, and where the proportion of people with DR will be lower. The time to obtain quality retinal images with FOP NM camera is also longer than with mydriatic cameras.

## Conclusion

To conclude, the smartphone-based nonmydriatic camera produced good quality images and demonstrated high sensitivity and specificity for the detection of STDR in this setting. Unlike desktop cameras, it is considerably lighter and does not need high technical skills necessary for handheld cameras. This portable, low-cost smartphone-based nonmydriatic camera can possibly be utilized as a screening tool

for DR, especially in rural areas in the low- and middle-income countries where trained personnel are scarce.

## Acknowledgments

We acknowledge the help of the optometrists at Dr.Mohan's Diabetes Specialities Centre, Gopalapuram Chennai for performing the digital retinal color photography for all the study participants with Remidio Fundus on phone non-mydriatic camera and Zeiss camera. The operational research project on Diabetic retinopathy was supported by a grant from Indian Institute of Public Health (Hyderabad) and Queen Elizabeth Diamond Jubilee Trust, London, UK.

## Financial support and sponsorship

The Queen Elizabeth Diamond Jubilee Trust, London, UK.

## Conflicts of interest

There are no conflicts of interest.

## References

1. Cho NH, Shaw JE, Karuranga S, Huang Y, da Rocha Fernandes JD, Ohlrogge AW, *et al.* IDF Diabetes atlas: Global estimates of diabetes prevalence for 2017 and projections for 2045. *Diabetes Res Clin Pract* 2018;138:271-81.
2. Yau JWY, Rogers SL, Kawasaki R, Lamoureux EL, Kowalski JW, Bek T, *et al.* Global prevalence and major risk factors of diabetic retinopathy. *Diabetes Care* 2012;35:556-64.
3. Goh JK, Cheung CY, Sim SS, Tan PC, Tan GS, Wong TY. Retinal Imaging techniques for diabetic retinopathy screening. *J Diabetes Sci Technol* 2016;10:282-94.
4. Fenner BJ, Wong RL, Lam WC, Tan GS, Cheung GC. Advances in retinal imaging and applications in diabetic retinopathy screening: A Review. *Ophthalmol Ther* 2018;7:333-46.
5. Panwar N, Huang P, Lee J, Keane PA, Chuan TS, Richhariya A, *et al.* Fundus photography in the 21<sup>st</sup> Century-A review of recent technological advances and their implications for worldwide healthcare. *Telemed J E Health* 2016;22:198-208.
6. Gupta V, Bansal R, Gupta A, Bhansali A. Sensitivity and specificity of non-mydriatic digital imaging in screening diabetic retinopathy in Indian eyes. *Indian J Ophthalmol* 2014;62:851-6.
7. Rajalakshmi R, Subashini R, Anjana RM, Mohan V. Automated diabetic retinopathy detection in smartphone-based fundus photography using artificial intelligence. *Eye (Lond)* 2018;32:1138-44.
8. Natarajan S, Jain A, Krishnan R, Rogye A, Sivaprasad S. Diagnostic accuracy of community-based diabetic retinopathy screening with an offline artificial intelligence system on a smartphone. *JAMA Ophthalmol* 2019. doi: 10.1001/jamaophthalmol. 2019.2923.
9. Rajalakshmi R, Arulmalar S, Usha M, Prathiba V, Kareemuddin KS,

- Anjana RM, *et al.* Validation of smartphone based retinal photography for diabetic retinopathy screening. *PLoS One* 2015;10:e0138285.
10. Wilkinson CP, Ferris FL III, Klein RE, Lee PP, Agardh CD, Davis M, *et al.* Proposed international clinical diabetic retinopathy and diabetic macular edema disease severity scales. *Ophthalmology* 2003;110:1677-82.
  11. Early Treatment Diabetic Retinopathy Study Research Group. Photocoagulation for diabetic macular edema: Early treatment diabetic retinopathy study report number 1. *Arch. Ophthalmol* 1985;103:1796-806.
  12. Scanlon PH, Malhotra R, Greenwood RH, Aldington SJ, Foy C, Flatman M, *et al.* Comparison of two reference standards in validating two field mydriatic digital photography as a method of screening for diabetic retinopathy. *Br J Ophthalmol* 2003;87:1258-63.
  13. Kim TN, Myers F, Reber C, Loury PJ, Loumou P, Webster D, *et al.* A smartphone-based tool for rapid, portable, and automated wide-field retinal imaging. *Transl Vis Sci Technol* 2018;7:21.
  14. Saldanha MJ, Meyer-Bothling U. Outcome of implementing the national services framework guidelines for diabetic retinopathy screening: Results of an audit in a primary care trust. *Br J Ophthalmol* 2006;90:122.
  15. Bedard C, Sherry Liu S, Patterson C, Gerstein H, Griffith L. Systematic review: Can non-mydriatic cameras accurately detect diabetic retinopathy? *Diabetes Res Clin Pract* 2017;129:154-59.
  16. Gosheva M, Klameth C, Norrenberg L, Clin L, Dietter J, Haq W, *et al.* Quality and learning curve of handheld versus stand-alone non-mydriatic cameras. *Clin Ophthalmol* 2017;11:1601-6.
  17. Zhang W, Nicholas P, Schuman SG, Allingham MJ, Faridi A, Suthar T, *et al.* Screening for diabetic retinopathy using a portable, noncontact, non-mydriatic handheld retinal camera. *J Diabetes Sci Technol* 2016;11:128-34.
  18. Sengupta S, Sindal MD, Besirli CG, Upadhyaya S, Venkatesh R, Niziol LM, *et al.* Screening for vision-threatening diabetic retinopathy in South India: Comparing portable non-mydriatic and standard fundus cameras and clinical exam. *Eye (Lond)* 2018;32:375-83.
  19. Ryan ME, Rajalakshmi R, Prathiba V, Anjana RM, Ranjani H, Narayan KM, *et al.* Comparison among methods of retinopathy assessment (CAMRA) study: Smartphone, non-mydriatic, and mydriatic photography. *Ophthalmology* 2015;122:2038-43.